AST | AMERICAN SOCIETY OF TRANSPLANTATION

Prolonged VA ECMO as a bridge to heart-lung transplantation

Nicholas Braus, MD
Fellow
Division of Pulmonology & Critical Care
Mayo Clinic
Rochester, MN

CEOT CUTTING EDGE of TRANSPLANTATION

TRANSPLANT SUMMIT 2018

Breaking Through Regulatory Barriers to Unleash Transplant Innovation

FEBRUARY 8–10, 2018

ARIZONA BILTMORE • PHOENIX, AZ

Disclosures

None

23 year old female with pulmonary arterial hypertension

- ASD and VSD diagnosed at birth, unrepaired
- Non-smoker, only child, mother had childhood VSD repair
- Soon after graduating from high school, developed rapidly progressive exertional dyspnea
- Diagnosed with pulmonary hypertension (mPAP 64, normal PCW, CI 2.87)
- Treated locally with oral treprostinil and riociguat, eventually transitioned to IV epoprostenol

Transplant Evaluation

- Chronic hypoxemia on 4 Lpm supplemental O2
- NYHA class 3 symptoms on IV epo and riociguat
- TTE:
  - VSD with bidirectional shunt
  - Stretched PFO with R→L shunt
  - RV dysfunction (RVEF 19% on MRI)
- Cath: RAP 11, RVSP 92, PVR 12 WU, CI 3.1
- BMI 17, Blood group O, no transfusions or pregnancy
- 6MWD 1170ft/356m
- Listed for Heart-Lung Transplant, status 1B

Hospitalization

- One month later hospitalized for acute respiratory failure due to decompensated RV failure
- 100 FiO2 via HHFNC, milrinone and dopamine
- Status changed to 1A
- 6 days later developed refractory hypotension and hypoxemia
- Struggling on bi-level NIPPV, NE, Epi
- To OR for central VA ECMO initiation
  - Primary median sternotomy
  - Sub-sternal tunneled 16Fr venous and 28Fr arterial catheters

ECMO Course

- Day 2: Extubated
- Day 3: standing, transfer to chair
- Day 10: ambulatory without supplemental oxygen
- Day 30: ambulatory outside in hospital courtyard
- Day 150: oxygenator change-out
- Complications:
  - Lagging BMI, 14-17 with parenteral and enteral support
  - Intermittent infections around cannulae
  - Intermittent transfusions, goal Hgb 6

Transplant

- Suitable organs identified on ECMO day 248
- CMV D+/R-, EBV D+/R+
- Challenging procedure due to mediastinal and hilar adhesions and coagulopathy, central VA-ECMO re-instated due to refractory hypoxemia
- Retrospective crossmatch positive, plasmapheresis/ATG
- RUL hemorrhage → serial bronchoscopies
- ECMO weaned post-transplant day 18
- Delayed sternal wound closure with pectus flap, day 25
- Extubated post-transplant day 32
- Discharged on hospital day 325, post-transplant day 59

ECMO Bridge to Transplant

- Limited organ availability, long waitlist times and high mortality have spurred interest in advanced bridging therapies, including ECMO

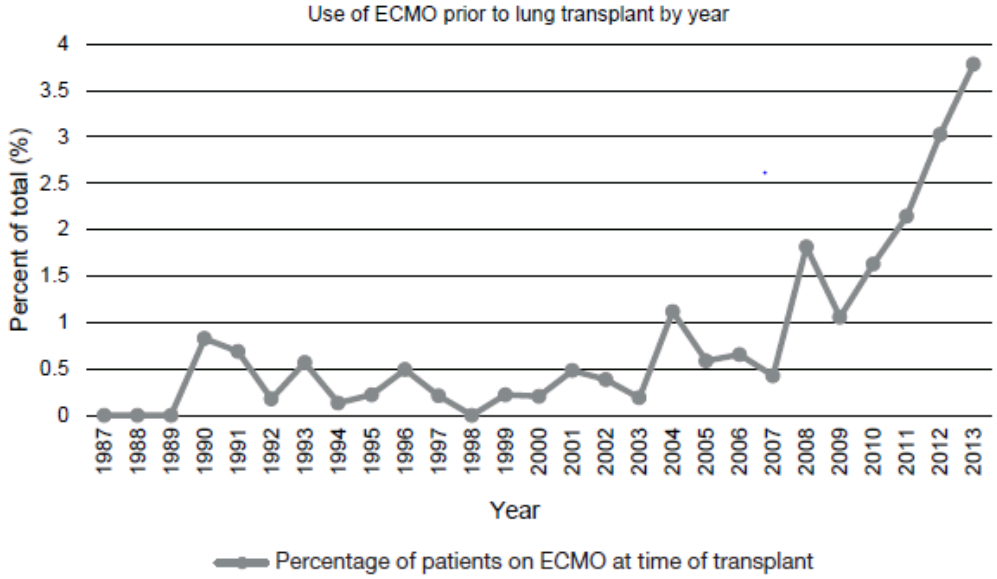

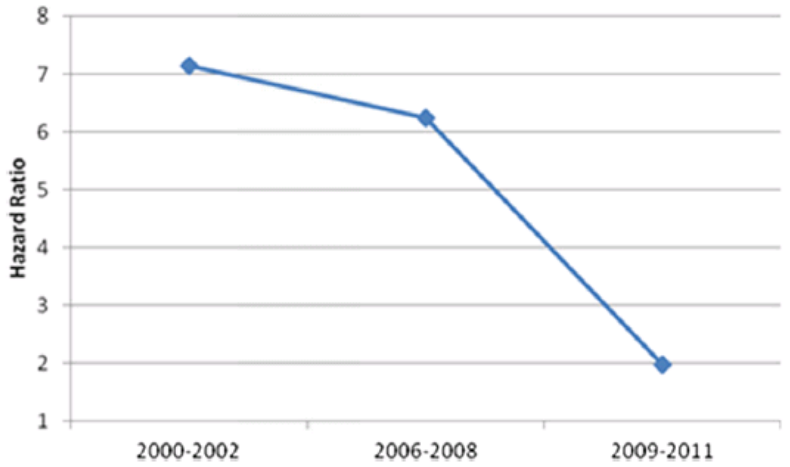

FIGURE 2. Trends in significant HR of 1-year mortality after transplantation for supported with ECMO compared with patients not supported with ECMO.

Gulack, J Thorac Dis 2014;6(8):1070-79

Hayanga, J Thorac Cardiovasc Surg 2015;149:291-6

Prolonged ECMO Bridging?

Technical improvements:

- Hollow fiber oxygenators
- Dual-lumen cannulas
- Levitated centrifugal pumps
- Heparin-bonded circuits
- Lung protective ventilation

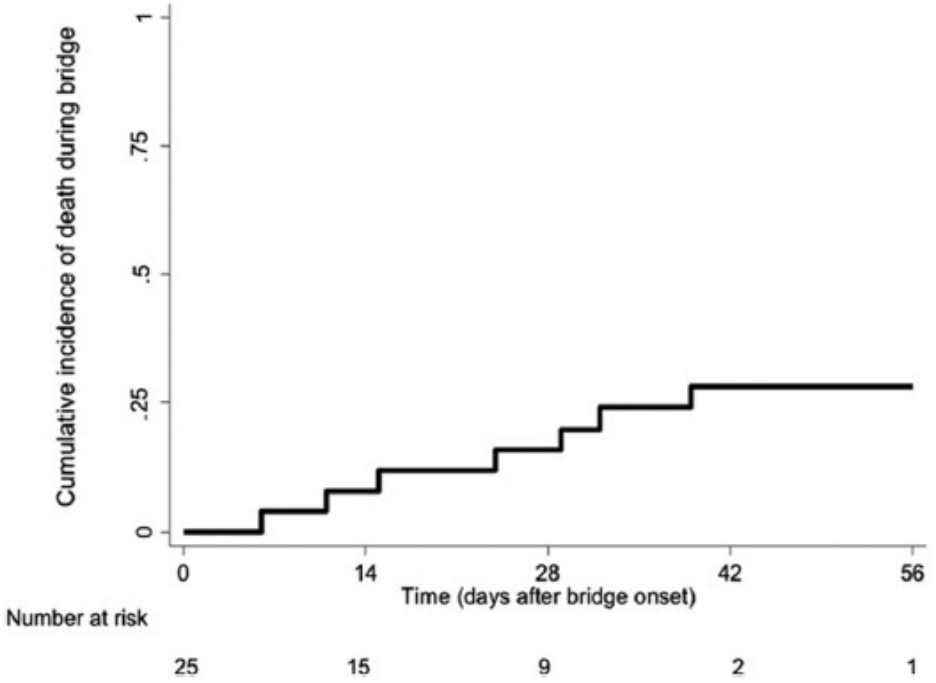

FIGURE 5. Cumulative incidence of death during bridge in the first 8 weeks, using a competing risk approach (transplant was considered a competing risk). The 8-week period was chosen because 24 of 25 patients either received a transplant or died within this bridge period (one patient died during bridging after 22 weeks).

Crotti, Chest 2013;144(3):1018-25

The Future of MCS→Lung Transplant

- BTT-ECMO >> BTT-MV?
- BTT-ECCO2R?

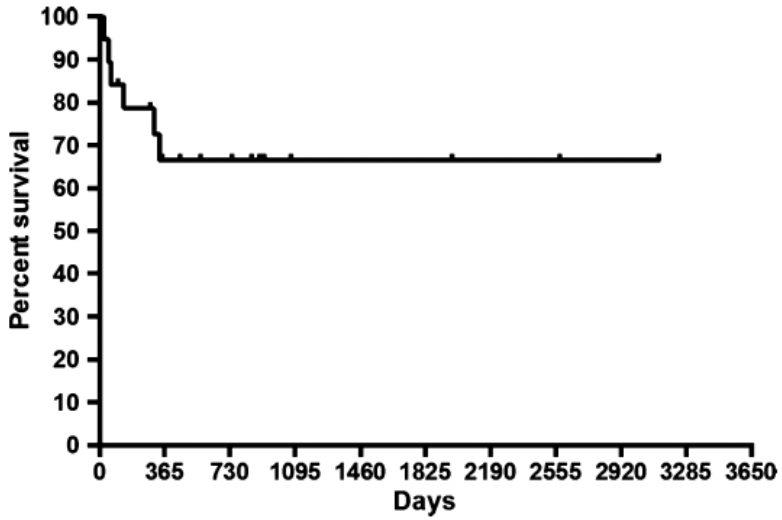

Figure 1 Long-term survival of patients receiving extracorporeal CO_2 removal as bridge to lung transplantation as analyzed by the method of Kaplan and Meier. Survival was 79% after 6 months and 67% after 12 and 24 months, respectively.

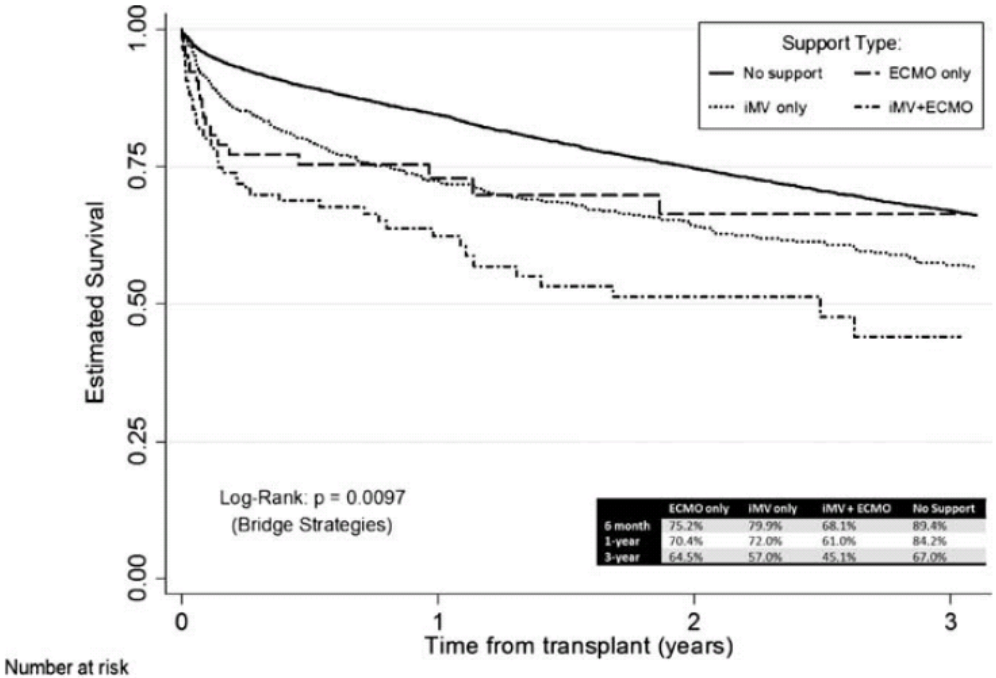

	ECMO only	iMV only	iMV + ECMO	No Support
6 month	75.2%	79.9%	68.1%	89.4%
1-year	70.4%	72.0%	61.0%	84.2%
3-year	64.5%	57.0%	45.1%	67.0%

Number at risk

No support	11545	7956	5702	4066
ECMO only	65	27	19	11
iMV only	612	377	256	172
iMV+ECMO	119	42	23	11

Schechter, Transplantation, 2016;100: 2699–2704
Steunstichting, Transplant Int, 2015;28:297–304

Thank you

Dr. Martin Zamora
Dr. Greg Schears
Dr. Paul Mueller
American Society of Transplantation
Cutting Edge of Transplantation 2018